

Management of Hollow Viscous Gastric and Duodenal Perforation Cases by Surgical Method versus Non-Operative Management: A Comparative Study

N Durgaprasad¹, V Manmadharao², K Babji³, K Satyarao⁴

¹Assistant Professor, Department of General Surgery, Rangaraya Medical College, Kakinada, Andhra Pradesh, India, ²Associate Professor, Department of General Surgery, Rangaraya Medical College, Kakinada, Andhra Pradesh, India, ³Professor, Department of General Surgery, Rangaraya Medical College, Kakinada, Andhra Pradesh, India, ⁴Junior Resident, Department of General Surgery, Rangaraya Medical College, Kakinada, Andhra Pradesh, India

Abstract

Background: Upper gastrointestinal hollow viscous perforation is multifactorial and not fully understood even today. Hollow viscous perforation of upper gastrointestinal i.e. Gastric and duodenal perforations presents to the causality with acute abdominal pain and distension, hypotension and prostration.

Aims: The purpose of this study is to compare the outcome in patients with gastric or duodenal perforation by non-operative management as against definitive surgery.

Materials and Methods: A prospective study of upper gastrointestinal hollow viscous perforation cases was undertaken in Government General Hospital, Kakinada. 100 cases of perforation of duodenum and stomach have been included in this study. Of them, 70 cases were managed by definitive surgery, and 30 cases were unfit to undergo an anesthetic and surgical line of management. This group was managed by bilateral flank drains. Follow-up regarding recovery was observed.

Results: Maximum age incidence of hollow viscous perforation (gastric and duodenal) is between 35 and 45 years. Maximum sex incidence is in males - 80%. Of these 30 patients was managed by non-operative method. Non-operative management was successful in total recovery in 66.66% of patients, which is very significant. Out of the survived cases maximum number are at the age of 35-45 years.

Conclusions: Non-operative management, by keeping bilateral flank drains, is a formidable line of management as an alternative to surgical management in patients with compromised general condition, unfit for any type of anesthesia.

Key words: Definitive surgery, Hollow viscous perforation, Laparotomy

INTRODUCTION

Hollow viscous perforation of upper gastrointestinal, i.e. Gastric and duodenal perforations presents to the causality with acute abdominal pain and distension,

hypotension and prostration. Usually, there is a prior history of symptoms suggestive of acid peptic disease or analgesic over usage.^{1,2}

On examination, upper abdominal tenderness, guarding, rigidity and obliterated liver dullness are the cardinal clinical features. Plain X-ray abdomen in an erect posture shows crescentic gas shadow under the right dome of diaphragm.^{3,4} Intravenous fluid infusion with correction of electrolyte imbalance is the immediate priority in management. Other accessory measures of colloid or crystalloid infusion to treat hypovolemia and shock and packed red blood cell transfusion is important to make the patient fit for anesthesia.⁵⁻⁷

Access this article online



www.ijss-sn.com

Month of Submission : 12-2014
Month of Peer Review : 01-2015
Month of Acceptance : 01-2015
Month of Publishing : 01-2015

Corresponding Author: Dr. N Durgaprasad, D. No: 11-245, Venkataramana Nagar, Indrapalem, Kakinada, East Godavari - 533 004, Andhra Pradesh, India. Phone: +91-9848160946. E-mail-dprasad_dr@yahoo.com

MATERIALS AND METHODS

A total of 100 cases of perforation of duodenum and stomach have been included in this study. Ethics the protocol was approved by the Local Committee and written informed consent was obtained from each patient. Out of them, 70 cases were managed by definitive surgical method by laparotomy and closure of the perforation with Graham's Omental onlay patch repair. Thirty cases were unfit to undergo an anesthetic and surgical line of management. Hence, bilateral large bore drains were kept in the flanks by blind method under local infiltrative lignocaine analgesia. The outcome was closely followed up to record the prognosis and recovery. For all patients anti *Helicobacter pylori* treatment are given as a protocol post-operatively at the time of discharge.

RESULTS

A study of 100 cases of hollow viscous perforation in stomach and duodenum was carried, out of which 80 are males and 20 females. Operative management was done in 70 cases, and non-operative management was done in 30 patients.

The patients age group was divided into different categories ranging from below <35 years to >75 years (Table 1).

Out of 100 samples for study males patients were 80 in number, while female patients were 20 in number. The pie chart represents the study sample (Figure 1).

The site of perforation, which was involved in study sample was found to be in five patients in the gastric region and 65 in duodenal regions (Figure 2).

Various reasons for morbidities have been mentioned in percentage in Table 2 and represented in graphical format (Figure 3).

Time at which oral fluids were allowed to patients. For operated patients on 4th post-operative day and for non-operated patients: on 7th post-operative day (Figure 4).

Maximum death rates after non-operative management occurred in patients above 45 years i.e., 8/10 are represented in Table 3, Figure 5a and b.

DISCUSSION

The etiology of upper gastrointestinal hollow viscous perforation is multi-factorial and not fully understood even today. It has been observed that treatment of acid

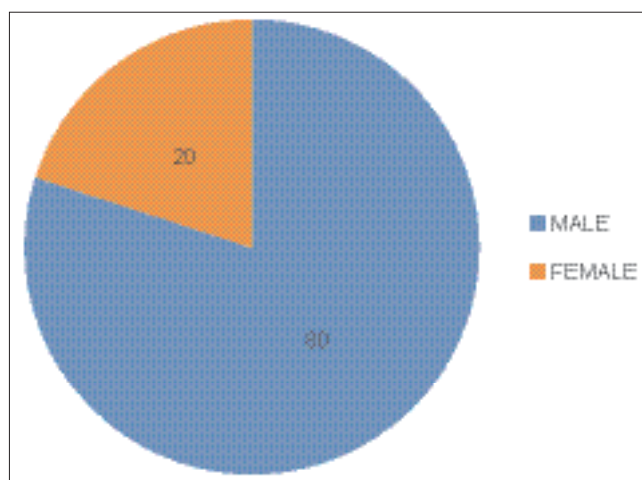


Figure 1: Sex incidence

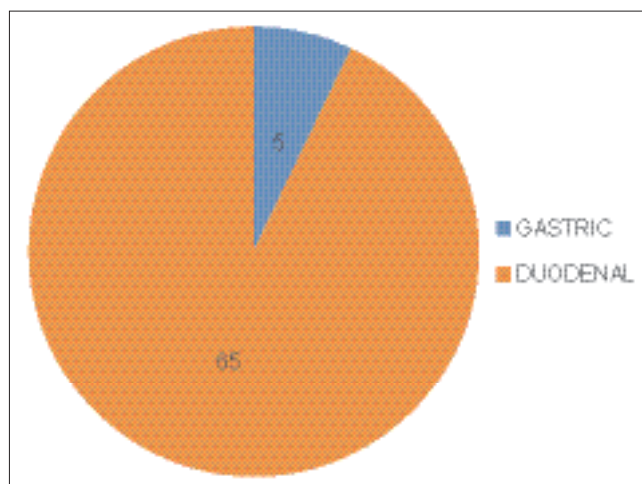


Figure 2: Site of perforation

Table 1: Age incidence of patients with HVP (gastric and duodenal)

Age (years)	Male (80)	Female (20)	Operative management (70)	Number of deaths after surgery (10)	Non-operative management (30)	Number of deaths after non-operative management (10)
<35	10	Nil	8	1	2	Nil
35-45	50	6	40	5	16	2
46-55	10	12	17	2	5	3
56-65	5	2	4	2	3	2
66-75	2	Nil	1	Nil	1	1
>75	3	Nil	Nil	Nil	3	2

HVP: Hollow viscous perforation

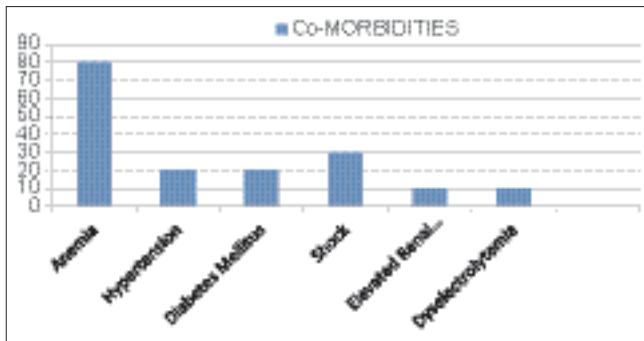


Figure 3: Co-morbidities

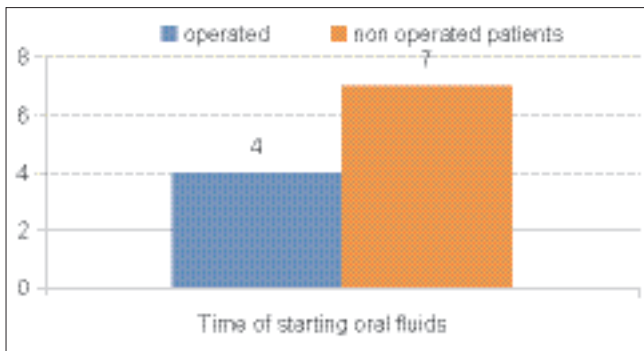


Figure 4: Time at which oral fluids was allowed to patients

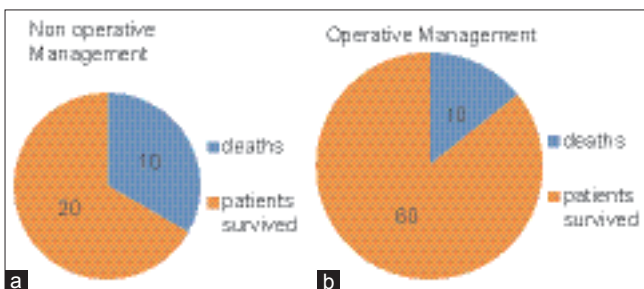


Figure 5: (a) Non-operative management (b) Operative management deaths

Table 2: Co-morbidities

Co-morbidities	Percentage
Anemia	80
Hypertension	20
Diabetes mellitus	20
Presentation with shock (SBP<80 mm of Hg)	30
Elevated renal parameters	10
Dyselectrolytemia	10

SBP: Systolic blood pressure

Table 3: Maximum death rates after non-operative management

Type of management	Number of patients survived	Number of patients died	Total
Non-operative	20	10	30
Operative	60	10	70

peptic disease, non-ulcer dyspepsia with proton pump inhibitors and anti-*H. Pylori* treatment with triple therapy in selected cases also has not brought big changes in the incidence of perforation as a complication. Hence, the incidence of duodenal perforation is still high.^{8,9} Acute or long standing usage of analgesics especially non-steroidal anti-inflammatory drug such as diclofenac sodium, alcohol abuse, smoking tobacco and male sex are other proposed causes responsible for acute duodenal perforation. Most commonly perforation is found typically in the first part of the duodenum just lateral to the vein of mayo. On laparotomy, reactive peritoneal fluid admixed with bile is a common finding. Sometimes, flakes of mucus mixed with organized fibrous tissue and omental adhesions are observed thus making it difficult to expose the perforation.¹⁰ The size of the perforation is usually 0.5 cm to sometimes as large as 2 cm, which allows undigested food material to contaminate the peritoneal cavity.^{11,12}

The perforation is closed after trimming the edges with a non-absorbable silk or delayed absorbable vicryl by simple suturing. An on-lay patch of the greater omentum from nearby greater curvature of the stomach is done to just transpose over the wound to ensure good vascularity and healing. Peritoneal lavage with saline is done, and a subhepatic drain is kept in situ and anchored securely to the abdominal wall. Post-operative follow-up with Ryle's tube aspiration for 48 h, fluid and electrolyte management, antibiotics are all meticulously followed.¹³

Non-Operative Management

In patients with high risk for anesthesia and surgery, with the reasons like severe non-responding hypotension, raised renal parameters, patients on anti-coagulant treatment, a non-operative management line is a better choice for such patients. Bilateral large bore polyvinyl chloride drains of 32G are kept into the peritoneal cavity simultaneously. Under local xylocaine, infiltrative analgesia with a skin incision drain ends are thrust into the peritoneal cavity, and drained fluid is collected into bags.¹⁴ After 48 h the drain output is measured and monitored. If the drain output decreases, patient circulatory status improves and bowel sounds return over the next few days explorative laparotomy is not undertaken. Conservative management by supportive care is provided. As the patient condition improves, the perforation is assumed to be closed spontaneously.¹⁵

CONCLUSION

Non-operative management by keeping bilateral flank drains of upper gastrointestinal hollow viscous perforation is a formidable line of management as an alternative to

surgical management in patients with compromised general condition, unfit for any type of anesthesia.

REFERENCES

1. Uccheddu A, Floris G, Altana ML, Pisanu A, Cois A, Farci SL. Surgery for perforated peptic ulcer in the elderly. Evaluation of factors influencing prognosis. *Hepatogastroenterology* 2003;50:1956-8.
2. Nogueira C, Silva AS, Santos JN, Silva AG, Ferreira J, Matos E, *et al.* Perforated peptic ulcer: Main factors of morbidity and mortality. *World J Surg* 2003;27:782-7.
3. Hermansson M, Staël von Holstein C, Zilling T. Surgical approach and prognostic factors after peptic ulcer perforation. *Eur J Surg* 1999;165:566-72.
4. Testini M, Portincasa P, Piccinni G, Lissidini G, Pellegrini F, Greco L. Significant factors associated with fatal outcome in emergency open surgery for perforated peptic ulcer. *World J Gastroenterol* 2003;9:2338-40.
5. Svanes C. Trends in perforated peptic ulcer: Incidence, etiology, treatment, and prognosis. *World J Surg* 2000;24:277-83.
6. Shan YS, Hsu HP, Hsieh YH, Sy ED, Lee JC, Lin PW. Significance of intraoperative peritoneal culture of fungus in perforated peptic ulcer. *Br J Surg* 2003;90:1215-9.
7. Crofts TJ, Park KG, Steele RJ, Chung SS, Li AK. A randomized trial of nonoperative treatment for perforated peptic ulcer. *N Engl J Med* 1989;320:970-3.
8. Berne TV, Donovan AJ. Nonoperative treatment of perforated duodenal ulcer. *Arch Surg* 1989;124:830-2.
9. Keane TE, Dillon B, Afdhal NH, McCormack CJ. Conservative management of perforated duodenal ulcer. *Br J Surg* 1988;75:583-4.
10. Donovan AJ, Berne TV, Donovan JA. Perforated duodenal ulcer: An alternative therapeutic plan. *Arch Surg* 1998;133:1166-71.
11. Marshall C, Ramaswamy P, Bergin FG, Rosenberg IL, Leaper DJ. Evaluation of a protocol for the non-operative management of perforated peptic ulcer. *Br J Surg* 1999;86:131-4.
12. Crofts TJ, Park KG, Steele RJ, Chung SS, Li AK. A randomized trial of nonoperative treatment for perforated peptic ulcer. *N Engl J Med* 1989;320:970-3.
13. Katkhouda N, Mavor E, Mason RJ, Campos GM, Soroushyari A, Berne TV. Laparoscopic repair of perforated duodenal ulcers: Outcome and efficacy in 30 consecutive patients. *Arch Surg* 1999;134:845-8.
14. Lee FY, Leung KL, Lai PB, Lau JW. Selection of patients for laparoscopic repair of perforated peptic ulcer. *Br J Surg* 2001;88:133-6.
15. Bergamaschi R, Mårvik R, Johnsen G, Thoresen JE, Ystgaard B, Myrvold HE. Open vs laparoscopic repair of perforated peptic ulcer. *Surg Endosc* 1999;13:679-82.

How to cite this article: Durgaprasad N, Manmadharao V, Babji K, Satyarao K. Management of Hollow Viscous Gastric and Duodenal Perforation Cases by Surgical Method versus Non-Operative Management: A Comparative Study. *Int J Sci Stud* 2015;2(10):86-89.

Source of Support: Nil, **Conflict of Interest:** None declared.