

# Functional Outcome of Complex Tibial Plateau Fractures Using Hybrid External Fixators

G A Rajmohan<sup>1</sup>, M C Chinnadurai<sup>2</sup>

<sup>1</sup>Associate Professor of Orthopaedics, Thanjavur Medical College, Thanjavur, <sup>2</sup>Assistant Professor of Orthopaedics, Thanjavur Medical College, Thanjavur

## Abstract

**Introduction:** Tibial plateau fractures are associated with comminution and soft tissue injury and are usually managed with ORIF (Open Reduction and Internal Fixation). The hybrid external fixer helps to reduce the associated complications by allowing early mobilization and weight bearing, minimal soft tissue damage, and stable fixation. In this study, we assessed the complications, clinical outcome scores, and postoperative range of knee movements associated with Schatzker type 5 and 6 tibial fractures.

**Aim:** To study the functional outcome and role of hybrid external fixators in complex tibial plateau fractures.

**Methods:** The study included 75 patients with Schatzker type 5 and 6 fractures who underwent open/close reduction with a hybrid external fixator. Informed consent was obtained from all the patients and a 2 months post-operative follow-up was done. The analyses were performed with NEER's RATING SYSTEM FOR KNEE.

**Results:** The mean age of the patients was 51.28±14.28 years and a male predominance prevailed. RTA accounted for 68% of the fractures and with hybrid external fixator, excellent results were achieved in 60% of the cases. knee stiffness, pin site infection, malunion and limb shortening were the associated complications.

**Conclusion:** A promising alternative therapy for high-energy plateau fractures is a hybrid external fixator. It permits a safe fixation of fraction fragments, early joint recovery and the treatment of related soft tissue injuries with minimum complication rates.

**Key words:** Hybrid external fixation, complex tibial fractures, NEER's score, compound fracture, Schatzker type 5 and 6.

## INTRODUCTION

Complex tibial plateau fractures pose a therapeutic dilemma by presenting with significant articular and soft tissue damage. These high energy injuries are a threat to the major weight bearing joint. The management of these injuries is challenging to the orthopaedic surgeon as the restoration of the articular surface, joint stability, and axis are a complex procedure. In addition, associated soft tissue damage may further increase the complexity of the treatment<sup>[1,2]</sup>. The conventional approach to these fractures was an open reduction of the fragments and internal fixation with plates and screws. This was associated with

increased risk of wound complications and decreased or impaired functional range of movements of the associated joint. This led to the development of alternate methods of fixation like Ilizarov ring fixation, external fixation with limited internal fixation and hybrid external fixation<sup>[3]</sup>. These procedures have an advantage of early joint motion and stable fixation.

Road traffic accidents and fall injuries are the most common causes of high impact fractures and young middle-aged males are the most affected population. It can lead to prolonged disability and has a significant socio-economic effect in this population. Literature indicates that only 50% better results are achieved with closed or open surgical techniques<sup>[4]</sup>. Ordinary external fixators may lead to knee stiffness and are not suitable for type 5 and 6 fractures. ORIF, which was the attractive treatment method since 1990s, reduces the articular surfaces well but does not protect the surrounding soft tissue<sup>[5,6]</sup>. The advantage of hybrid external fixator is that it protects the soft tissue envelope and allows access to the soft tissue cover during treatment. Additional stability can

Access this article online



www.ijss-sn.com

**Month of Submission :** 11-2019  
**Month of Peer Review :** 12-2019  
**Month of Acceptance :** 12-2019  
**Month of Publishing :** 01-2020

**Corresponding Author:** Dr. M C Chinnadurai, Assistant Professor of Orthopaedics, Thanjavur Medical College, Thanjavur.

be attained with the use of cannulated screws and K-wires which will allow for early knee mobilization.

The aim of our study was to find out the functional outcomes after treatment with hybrid external fixators, with open reduction and closed reduction techniques by comparing the pre- and post-operative radiographs.

**Aim**

To study the functional outcome and role of hybrid external fixators in complex tibial plateau fractures.

**MATERIALS AND METHODS**

This prospective study was conducted in Department of Orthopaedics, Thanjavur Medical College, Thanjavur during the time period June 2018 to July 2019. Patients over 20 years of age and with fractures of the closed Tibial plateau (Schatzker type 5 and type 6) (grade I to grade III B) were included in the study. Patients of age < than 20 years, those with co-morbid conditions, shut-off shallow board fractures (Schatzker 1-4), compound grade IIIc shallow board fracture and floating knee and pilon fractures were excluded from the study. The fractures were treated with either closed reduction and hybrid external fixation or with minimal open reduction and a hybrid system. The patients were allowed to walk with walker's support with touch toe after reduction of symptoms. After 2 weeks, partial weight bearing walking with the help of walker was started and full-weight bearing walking with walker support was allowed at 6 weeks after surgery. Radiographic analysis showed fracture reunion at the end of 6 weeks. The Fixator was removed, and PTB cast was added to allow the patient to bear full weight. The PTB cast was removed after 2 weeks followed which the patients were advised to begin walking with a walker and to discard the walker gradually. Functional outcomes were assessed using NEER's rating score.

**RESULTS**

A total of 75 patients were included in the study of which 54 were males and 21 were females. The mean age of the patients was 51.28±14.28 years. 68% of the fractures were due to road traffic accidents and a majority of the cases (60%) were Schatzker type-6 high energy fractures of the tibial condyle. According to Neer's score rating system for knee, 60% patients had excellent and 29% patients had good outcome. 5% of patients had fair outcome and only 4% had poor outcome [Figure 1]. Out of the 75 cases, 30 cases were Type 5 and 45 cases were Type 6 Schatzker, and the average Neer's scoring for them was 18.25 and 13.50, respectively [Table 1]. 27 cases of closed fracture and 48 cases of compound fracture which were treated by hybrid fixator showed average Neer's score of 16.85 and 13.86, respectively [Table 2]. The most common

complication was knee stiffness (11%) followed by pin site infection (8%), that was overcome by regular dressing. Knee stiffness was managed by physiotherapy [Figure 2]. Wound infection was seen in 4% of the cases. Malunion and limb shortening was observed each in 3% of the cases.

**DISCUSSION**

The management of complex tibial plateau fractures is challenging and there is no clear consensus to the ideal treatment method till date. The treatment modality may vary

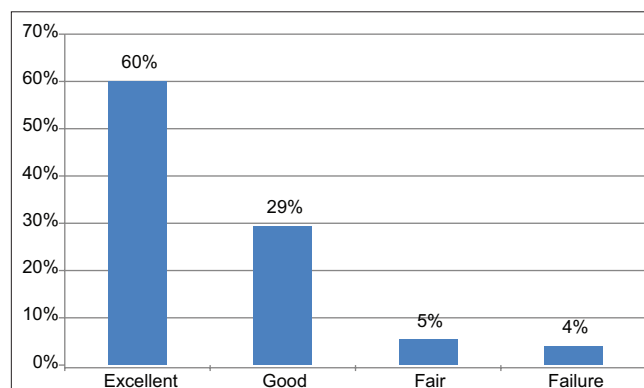


Figure 1: Distribution of NEER's Score

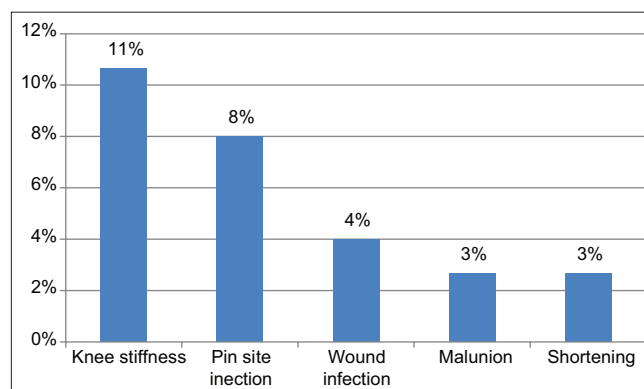


Figure 2: Complications

**Table 1: NEER's Rating Score according to Schatzker's type**

Schatzker's type	Number of cases	Average NEER's rating score
Type 5	30	18.25
Type 6	45	13.50

**Table 2: Results based on type of fracture (closed /open)**

Fracture	Number of cases	Average Neer's rating score
Closed fracture	27	16.85
Compound	48	13.86

from surgeon to surgeon. Review of literature suggests that open anatomical reduction of the articular surface is the gold standard for treating these injuries. Studies over the last 10 years suggest that minimally invasive or closed reduction with ring or hybrid external fixation is a safer equivalent to ORIF method for treating Schatzker Type V and VI fractures<sup>[7,8]</sup>. Extensive soft tissue damage may be associated with these fractures and maintaining their integrity plays a vital role in fracture healing. The average fracture healing time ranges from 6 to 10 weeks and preservation of the fracture haematoma aids in early reunion. Factors like the type of fracture and presence of infection may interfere with the healing process. Good anatomical reduction and stable fixation can reduce the complications and also has early rehabilitative effects<sup>[9,10]</sup>. Studies show that these effects can be achieved with the use of hybrid external fixators.

Hybrid external fixators are easy to use and they have been used for the management of complex and compound tibial condyle fractures in the recent years. The procedure is also associated with lower blood loss compared with ORIF for plating and can minimize skin necrosis. Avoiding skin necrosis is an inevitable factor in these injuries as that could be an issue in the proximal tibia, that offers space for covering skin/flaps in cases of skin loss/bone exposed compound fractures<sup>[11]</sup>. In our study, excellent results were achieved in 60% of the cases and good outcome in 29% cases with the use of hybrid external fixator as per NEER scoring system of knee. A 4% failure rate was observed in our study. An average NEER score of 18.25 and 13.50 were found in Type 5 & 6 Schatzker fractures respectively. This shows that the functional outcomes were slightly better in type-5 fractures than the latter. The average NEER score with closed fracture was 16.85 and with compound fracture was 13.86, indicating that the results were better in case of close fractures.

As with any other procedure, a few complications were associated in our study but were minimal or insignificant. The most common complication was knee stiffness (11%) followed by pin site infection (8%). Wound infection, malunion and shortening of the limb were the other complications noticed. But the symptoms reduced and the patients were able to walk without walker's support at the 6<sup>th</sup> post-operative week. The complications were managed by physiotherapy and proper wound dressings. Our study results are similar to the study findings of Krupp *et al.* In his study too, an early fracture reunion was observed with the use of

hybrid external fixator<sup>[12]</sup>. The role of external fixators, either half-pin or ring and wire, has been evaluated in various studies of complex tibial plateau fractures, and quite encouraging results have emerged. Several authors have reported good results using a hybrid or circular frame combined with minimal open reduction and percutaneous screw fixation. The limitation of the study is the shorter follow-up time that did not allow for long-term outcome assessment.

## CONCLUSION

A promising alternative therapy for high-energy plateau fractures is a hybrid external fixator. Without high complication rates, it permits a safe fixation of fracture fragments, early joint recovery and the treatment of related soft tissue injuries. The outcome was better in Type 5 and closed fractures than in type 6 and compound fractures respectively in this study. More studies to ensure optimal functional recovery and patient satisfaction are needed.

## REFERENCES

1. Papagelopoulos PJ, Partsinevelos AA, Themistocleous GS, Mavrogenis AF, Korres DS, Soucacos PN. Complications after tibia plateau fracture surgery. *Injury*. 2006; 37: 475–84.
2. Benirschke SK, Agnew SG, Mayo KA, Santoro VM, Henley MB. Immediate internal fixation of open, complex tibial plateau fractures: treatment by a standard protocol. *Trauma*. 1992; 6:78–86.
3. Mallik AR, Covall DJ, Whitelaw GP. Internal versus external fixation of bicondylar tibial plateau fractures. *Orthop Rev*. 1992; 21:1433–6.
4. Sirkin MS, Bono CM, Reilly MC, Behrens FF. Percutaneous methods of tibial plateau fixation. *Clin Orthop Relat Res* 2000; 375:60-8.
5. Weiner LS, Kelley M, Yang E, Steuer J, Watnick N, Evans M, *et al.* The use of combination internal fixation and hybrid external fixation in severe proximal tibia fractures. *J Orthop Trauma* 1995; 9:244-50.
6. Bianchi-Maiocchi A, Aronson J. *Operative Principles of Ilizarov*. Baltimore: Williams & Wilkins; 1991.
7. Piper KJ, Won HY, Ellis AM. Hybrid external fixation in complex tibial plateau and plafond fractures: An Australian audit of outcomes. *Injury*. 2005; 36:178–84. [PubMed] [Google Scholar]
8. Watson JT, Ripple S, Hoshaw SJ, Fhyrie D. Hybrid external fixation for tibial plateau fractures: Clinical and biomechanical correlation. *Orthop Clin North Am*. 2002; 33:199–209. ix.
9. Karunakar MA, Bose MJ. *Rockwood and Greens Fracture in Adults*. 5th ed. Ch. 231-245. Philadelphia, PA: Lippincott Williams & Wilkins; 2001.
10. Farrar M, Yang L, Saleh M. The Sheffield hybrid fixator – A clinical and biomechanical review. *Injury* 2001;32 Suppl 4:SD8-13.
11. Schatzker J, Mc Broom R, Bruce D. The tibial plateau fracture: the Toronto experience: 1968–1975. *Clin Orthop Relat Res*. 1979; 138:94–104.
12. Krupp RJ, Malkani AL, Roberts CS, Seligson D, Crawford CH, 3<sup>rd</sup>, Smith L. Treatment of bicondylar tibia plateau fractures using locked plating versus external fixation. *Orthopedics*. 2009;32: 559.

**How to cite this article:** Rajmohan GA, Chinnadurai MC. Functional Outcome of Complex Tibial Plateau Fractures Using Hybrid External Fixators. *Int J Sci Stud* 2020;7(10):129-131.

**Source of Support:** Nil, **Conflicts of Interest:** None declared.